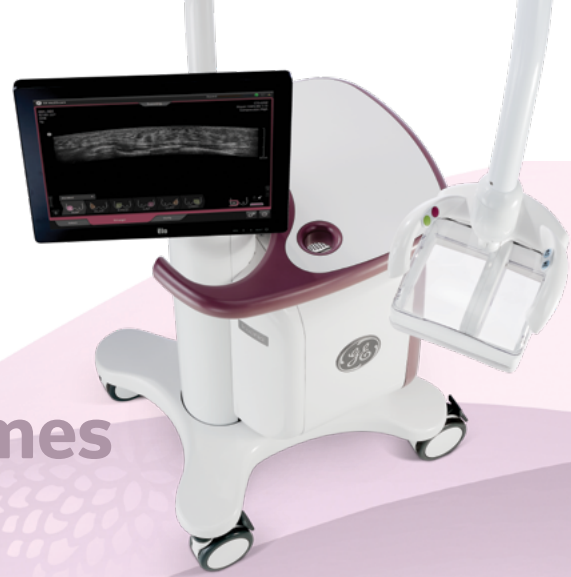



Using 3D ABUS to achieve improved breast care outcomes

Breast imaging expert panel



Breast cancer remains the most common cancer amongst women across Europe, with an estimated 494,000 new cases per year.¹ In the “Position Paper on Screening for Breast Cancer” published in *European Radiology*, EUSOBI (European Society of Breast Imaging) attributes a 40% reduction in breast cancer mortality based on population-based screening.²

Mammography has been proven to save lives by finding cancers when they are small enough to treat – but can we do better? Can we reduce the cancers that might be missed due to dense breast tissue using supplemental screening tools, such as 3D automated breast ultrasound (ABUS)?³

In advance of this year’s EUSOBI annual scientific meeting, five of Europe’s leading breast imaging experts participated in a virtual panel to discuss a variety of clinical topics associated with delivering the best possible breast health care, including a multi-modality approach to screening and the emergence of 3D ABUS as a promising new tool for screening women with dense breasts:

Participants

Prof. László Tabár, MD, Radiologist

Professor Emeritus of Radiology: Uppsala University, Faculty of Medicine, Sweden

Prof. Alexander Mundinger, MD, Radiologist

Director of Radiological Center Niels-Stensen-Clinics and Head of Imaging and Minimal-Invasive Breast Section, Breast Centre Osnabrueck.
Past President of Senologic International Society

Dr. Brigitte Wilczek, MD, PhD, Radiologist

Senior Breast Radiologist at Södersjukhuset Breast Center, Stockholm, Sweden

Dr. Athina Vourtsis, MD, PhD, Radiologist

Diagnostic Mammography, Athens, Greece.
Founding President of the Hellenic Breast Imaging Society

Prof. Dr. Thomas Frauenfelder, MD, Radiologist

Vice Director, Institute of Diagnostic Radiology, University Hospital, Zuerich, Switzerland

What do radiologists need to know about breast density?

Prof. Tabár: Since breast cancer is a heterogeneous disease and the normal breast parenchyma is heterogeneous, certain subtypes of the disease are not detectable by mammography (those hidden in the dense fibroglandular tissue). Every radiologist who reads a mammogram needs to know that about every third breast cancer is hidden by the dense fibroglandular tissue to the extent that they will miss the disease if only mammography is used to image the breast. Therefore, another diagnostic tool needs to be added to mammography: we need a multimodality approach for screening.

Prof. Mundinger: Supplemental 3D ABUS can increase the detection rate in women with dense breasts. Therefore, the rate of interval cancers should decrease in a screening program.

“We need a multimodality approach for screening”

– Prof. Tabár

Can you describe the importance of the 3D ABUS Somolnsight and EASY studies to a multi-modality approach to screening?



Dr. Wilczek: Results from multiple large scale screening ultrasound studies involving thousands of women demonstrate that ultrasound improves cancer detection as a supplement to mammography. The EASY Study (European Asymptomatic Screening Study) study published in *European Journal of Radiology* shows that it is feasible to implement 3D

ABUS into a high-volume mammography center and increase the cancer detection rate while maintaining a low recall rate well within the recommendations of the European guidelines for quality assurance in breast cancer screening and diagnosis.⁴ This is very consistent with the results of the Somolnsight study by Brem et al., published in *Radiology*, and the reader performance studies by Skaane et al., published in *Acta Radiologica*, and Giger et al., published in the *American Journal of Roentgenology*. All three studies concluded that adding 3D ABUS to mammography improved the performance of mammographic interpretation.

[Download the EASY Study](#)



Prof. Tabár: These were very well designed and carried out studies on large number of women with dense breast tissue. They showed 26-35% additional invasive cancers detected, respectively, when the mammograms failed to find these cancers.⁵ The conclusion was obvious: radiologists all over the world miss breast cancer that develops in dense fibroglandular

tissue. While the Somolnsight study showed high sensitivity, it also had a high recall rate (a typical American phenomenon). That triggered the European trial, which had an even higher cancer detection rate when using 3D ABUS in addition to FFDM, but it refuted the rumor that adding ABUS to FFDM will increase recall rate significantly; using only FFDM the recall rate was 2.1%, adding ABUS to it, the recall rate was 2.3%.

How is screening handled in countries that do not have a national regulated Breast Cancer Screening program?

Prof. Frauenfelder: Switzerland does not have a nation-wide breast cancer screening program. While there is one in French-speaking Switzerland, we perform opportunistic or personalized screening in Zurich. This means, women receive a mammogram due to their risk-profile, symptomatic complaints, or based on a personal request. With a personalized approach, we have the opportunity to offer a supplemental exam, such as 3D ABUS or 3D tomosynthesis, directly after the mammogram. This allows us to come to a diagnosis more quickly. While our goal is to provide personalized screening for each patient, we follow the quality standards associated with systematic screening.



Dr. Vourtsis: Like Switzerland, the health care system in Greece does not provide a national screening program. While the incidence of breast cancer in Greece is among the lowest of the 27 EU countries, it is important for women to have ongoing screening.⁶ This is why I have always performed an individualized approach to breast evaluation in my practice.

Throughout the years, I have informed my patients about their breast composition and the benefits of supplemental screening. Thus, our follow-up patients are well informed if they have dense breasts and they usually request to have both mammography and breast ultrasound during their visit.

[View A New Horizon for Breast Health article](#)



How did you decide to offer 3D ABUS for women with dense breasts? What are the clinical advantages of using 3D ABUS?

Prof. Frauenfelder: We are a training hospital with rotating residents. Since we often examine young women with fibroadenoma or cysts, breast ultrasound has always been important. Our challenge was that the user dependence of hand-held ultrasound (HHUS) led to additional recalls and tests. This was the main reason for the introduction of the Invenia™ ABUS into our department. Since ABUS acquires a 3D data set, the measurement of lesions is easier and more reproducible, which allows an objective comparison with priors. In addition, lesion positioning is well documented, so that a tissue-conserving operation is possible.

Dr. Vourtsis: We integrated the Invenia ABUS into our clinical practice in the beginning of 2016 and have performed more than 3,500 exams. 3D ABUS is a new tool that has been designed especially for screening. The sensitivity of 3D ABUS is

not affected by dense tissue, allowing the detection of non-calcified carcinomas that are obscured in mammography. Major advantages include that it provides volumetric global visualization of the whole breast in x, y and z planes, the exams are standardized and reproducible, enabling batch reading and double reading of 3D ABUS and allowing a comparison with previous volumes.

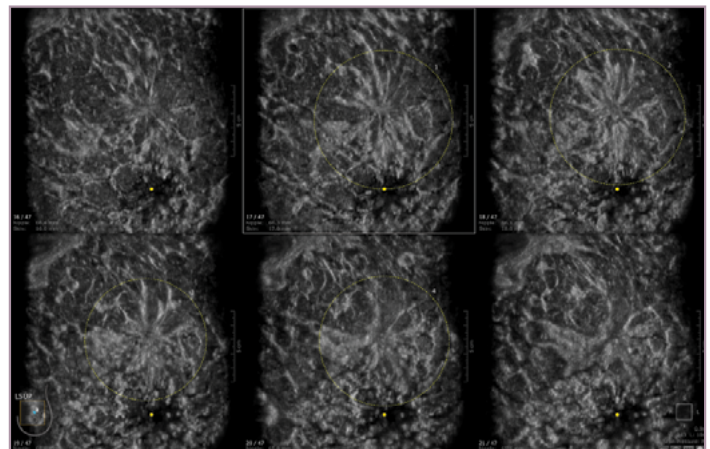
Prof. Munding: In our experience, 3D ABUS appears to assess the extent of invasive malignant lesions better than HHUS and correlates better than HHUS with the final pathologic measurement. We found that mean HHUS diameters of invasive tumors underestimated the final pathologic tumor diameter ($p < 0.05$) compared to the more accurate preoperative measurements of 3D ABUS.

How does the 3D ABUS coronal view help solve the problem of architectural distortions?

Prof. Tabár: Breast cancers originating from the major lactiferous ducts (ductal adenocarcinoma of the breast, DAB) account for about 20% of all breast cancer cases. They can be easily detected on the mammograms when they calcify, but there are some subtypes that do not calcify, instead, they form architectural distortion, which is difficult to visualize on the mammogram, even if they are extensive. ABUS is the method of choice in these cases since the main feature of this disease subtype is the large number of newly formed duct-like structures (neoductgenesis) that are easily detected on the 2 mm coronal slices.

Breast cancers, which have their origin in the mesenchyme are erroneously called “diffusely infiltrating lobular carcinoma” but are not formed in the lobules. They account for about 5% of all breast cancers, but the fatality rate among them is unacceptably high (40%). They are notoriously difficult to visualize on the mammogram, partly because there is no “early phase” or “small size”, since the entire connective tissue structure of the breast is involved from the inception of the malignancy. These will cause “architectural distortion” which can be very subtle, but they are detectable using 3D ABUS, which uses 2 mm thick coronal tissue slices.

Dr. Vourtsis: A study just published in *European Radiology*, entitled “[The performance of 3D ABUS versus HHUS in the visualization and BI-RADS® characterization of breast lesions in a large cohort of 1886 women](#)” highlights the value of 3D ABUS and its integration into clinical practice. The results of our study show that 3D ABUS yielded comparable results as HHUS in the detection and characterization of breast lesions, and in some patients proved to be superior to HHUS, especially in the detection of architectural distortions identified in the coronal reconstruction plane; a finding highly suspicious for malignancy.⁷ In three of our patients an architectural distortion was visualized on the coronal plane which was the only sign of an invasive lobular carcinoma and two radial scars which were not recognized in mammography or HHUS. Indeed, the coronal plane offers a new diagnostic challenge that cannot be obtained with traditional ultrasound.



ABUS coronal plane image showing architectural distortions.



What are the workflow advantages of using 3D ABUS compared to HHUS?

Prof. Frauenfelder: In Europe, HHUS exams must be acquired by physicians, which can often take up to 15 minutes. In contrast, 3D ABUS exams can be performed by a trained radiographer. This frees the radiologist to perform other procedures and to spend more time with patients. In addition to the workflow advantages, this also helps maintain quality and accuracy through systematic and objective assessment of the findings, even retrospectively. The ability to review the 3D ABUS data at any time and in any position, enables junior and senior radiologists to discuss images, which is common in mammography.

[View Prof. Frauenfelder's Video](#)



Dr. Vourtsis: As with every new imaging modality, there is a learning curve and interpretation time that varies among radiologists. Radiologists and technologists must receive training to acquire reproducible 3D ABUS examinations that increase the cancer detection rate and reduce the false positive and biopsy rates. Correlation with other imaging modalities (mammography, MRI) and the patient's clinical and personal information is essential. We adopted a standardized review protocol, which includes the review of the anterior posterior coronal plane followed by the transverse plane of each volume. Our interpretation time is approximately 3 minutes per examination, allowing an efficient integration of 3D ABUS into clinical workflow; particularly as the interpretation time was much less than when performing HHUS exams.

How do you use 3D ABUS for diagnostic exams? What is the benefit of using ABUS in the preoperative staging and surgical planning process?



Prof. Munding: In some patients with multifocal disease 3D ABUS detects more malignant foci than HHUS. Current data promise non-inferiority of ABUS compared to HHUS performed with standard quality systems.

It is important to evaluate all planes very thoroughly. Sometimes a cancer can be seen in one plane of one track only. The transversal

plane shows the best in-plane spatial resolution for detection of small cancers without architectural distortion. The coronal plane adds the diagnostic sign of a "star like" architectural distortion. This diagnostic sign is well established from older 3D studies. The 3D volume of ABUS is highly reproducible. The coronal plane allows a better perception of the segmental approach for visually gifted surgeons.

[Download Prof. Munding's Case Study](#)

How do you educate your patients about breast density and supplemental ABUS screening? What should patients know?

Dr. Vourtsis: Most women are not aware of the composition of their breast and how increased breast density may lead to a delayed diagnosis. When this important information is not delivered to women, it compromises their access to supplemental screening and its benefits.

In the US, advocacy groups have altered the information gap through breast density reporting legislation. In Japan, the ministry is preparing to issue guidelines on how local governments will notify women about the implications of breast density. Currently in the UK and Australia, advocacy groups are making great efforts to encourage the density discussion and to educate the public and healthcare professionals about the importance of density. In Europe, further communication efforts are needed in order to embrace breast density awareness to all European women.



Prof. Frauenfelder: It is important that women are informed in advance about the benefits of 3D ABUS because they otherwise have the feeling that they are not receiving the best care available. Additionally, the acceptance of the exam is very high, because the radiographers are often more emphatic than the radiologists, who are under time pressure.

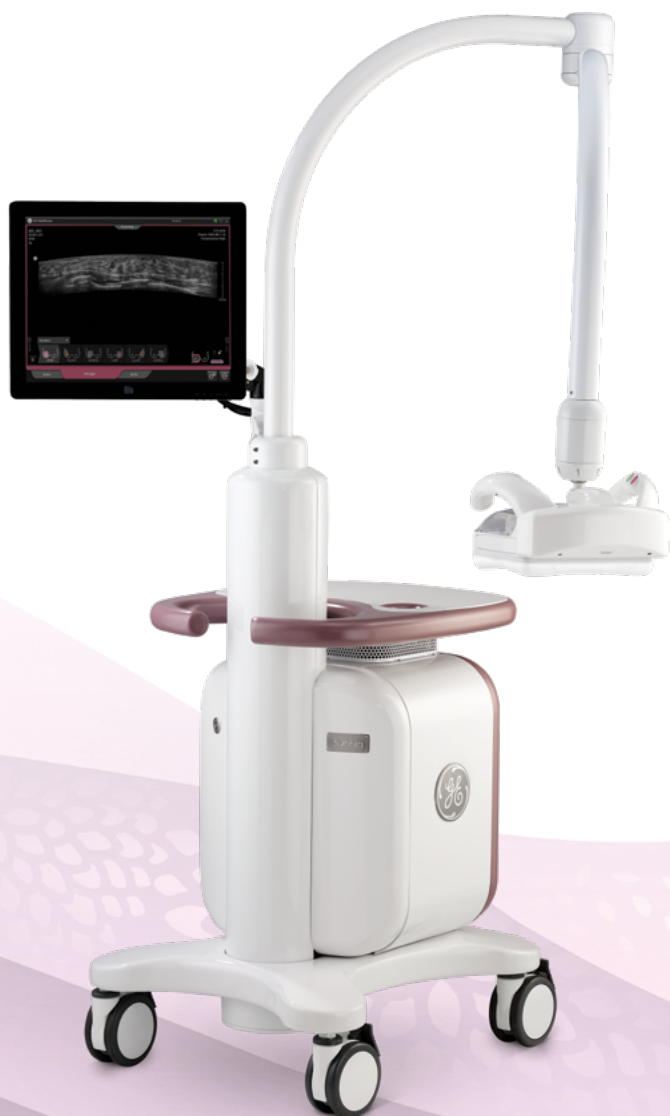

What do you see as the next steps to set a standard of care for screening women with dense breasts?

Prof. Tabár: Not recommending the use of a multimodality approach for screening following the publication of two peer reviewed, very convincing scientific trials can be called “the substandard of care.” It is simply not fair to send a “well letter” to a woman with dense fibroglandular tissue when we are aware of the fact that every third breast cancer will be missed hidden in the dense breast tissue.

Having read the content of this virtual panel, I hope that it is obvious for the reader that using the combination of two “different types of beams” (X-ray and ultrasound) need to be used on all women with dense breast tissue in order to provide a similarly high quality imaging result to all women, regardless of their risk level.

[View Prof. Tabár’s ABUS Education Lesson Video](#)

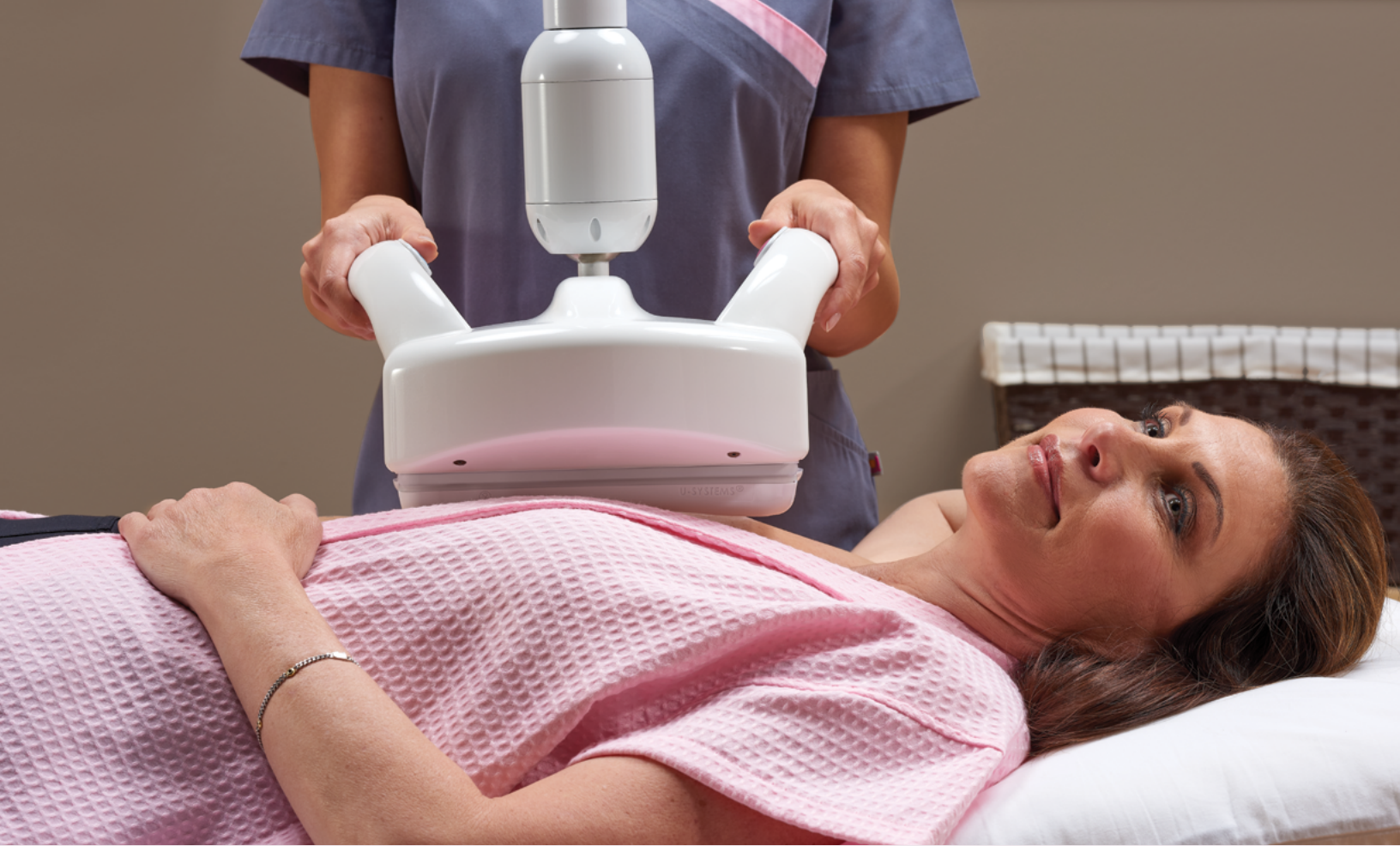

Dr. Wilczek: Hopefully, women with dense breasts outside the US will get to know about their breast density and personal risk and be offered additive methods to baseline screening mammography.

Delivering no additional radiation exposure, 3D ABUS is a wonderful screening tool. If ABUS would be a part of national screening programs for dense breasts, more cancers could be detected at an earlier stage. As a result, each woman should get a digital mammogram or a 3D tomosynthesis low dose exam each second year with an ABUS if she has a moderate risk or dense breasts. Women with high risk would be each year screened with MRI with abbreviated sequences.

Dr. Vourtsis: In Europe, in order to set a standard of care for screening women with dense breasts clear guidelines should be established between different countries. At the moment, we are working on creating a European coalition for breast density, which will be used to raise awareness both to physicians and to the general public about issues associated with breast density and the significant impact of supplemental screening in those women with dense breasts.





For women at increased risk of breast cancer, clinical studies have shown that screening technologies in addition to mammography may contribute to earlier detection, particularly in younger women for whom mammography is less sensitive.⁸ Factors that should be considered by clinicians include cleared and approved product labeling, recommendations and guidelines provided by medically sourced organizations, and the appropriateness when considering how they may apply to your organization or practice.

1. Ferlay J, Soerjomataram I, Ervik M, Dikshit R, Eser S, Maters C, Rebelo M, Parkin DM, Forman D, Bray, F. GLOBOCAN 2012 v1.0, Cancer Incidence and Mortality Worldwide: IARC CancerBase No. 11 [Internet]. Lyon, France: International Agency for Research on Cancer; 2013. Available from <http://globocan.iarc.fr>
2. Sardanelli, F., Aase, H.S., Álvarez, M. et al., Position paper on screening for breast cancer by the European Society of Breast Imaging (EUSOBI) and 30 national breast radiology bodies from Austria, Belgium, Bosnia and Herzegovina, Bulgaria, Croatia, Czech Republic, Denmark, Estonia, Finland, France, Germany, Greece, Hungary, Iceland, Ireland, Italy, Israel, Lithuania, Moldova, The Netherlands, Norway, Poland, Portugal, Romania, Serbia, Slovakia, Spain, Sweden, Switzerland and Turkey, *Eur Radiol* (2016). doi:10.1007/s00330-016-4612-z
3. Boyd, et al: Mammographic density and the risk and detection of breast cancer, *NEJM* Jan 2007
4. Wilczek Brigitte, Wilczek Henryk E, Rasouliyan Lawrence, Leifland Karin, Adding 3D Automated Breast Ultrasound to mammography screening in women with heterogeneously and extremely dense breasts. Report from a hospitalbased, high-volume, single-center breast cancer screening program., *European Journal of Radiology* <http://dx.doi.org/10.1016/j.ejrad.2016.06.004>
5. Brem RF, Tabár L, et al., Assessing Improvement in Detection of Breast Cancer with Three-dimensional Automated Breast US in Women with Dense Breast Tissue: The Somolnsight Study., *Radiology*. 2015 Mar; 274(3): 663-73
6. Ferlay J, Steliarova-Foucher E, Lortet-Tieulent J, et al., Cancer incidence and mortality patterns in Europe: estimates for 40 countries in 2012., *Eur J Cancer* 2013; 49: 1374-403
7. Vourtsis A, Kachulis, A., The performance of 3D ABUS versus HHUS in the visualization and BI-RADS characterisation of breast lesions in a large cohort of 1,886 women., *European Radiology*, 2017. ISSN 0938-7994 *Eur Radiol* DOI 10.1007/s00330-017-5011-9
8. Tagliafico, Massimo Calabrese et al, Adjunct Screening With Tomosynthesis or Ultrasound in Women With Mammography-Negative Dense Breasts: Interim Report of a Prospective Comparative Trial, *Journal of Clinical Oncology* 2016 34:16, 1882-1888

© 2017 General Electric Company – All rights reserved.

GE Healthcare reserves the right to make changes in specifications and features shown herein, or discontinue the product described at any time without notice or obligation. Contact your GE Healthcare representative for the most current information. GE and the GE Monogram are trademarks of General Electric Company. BI-RADS is a trademark of the American College of Radiology. Third party trademarks are the property of their respective owners. GE Healthcare, a division of General Electric Company. GE Medical Systems, Inc., doing business as GE Healthcare.

